

4. The Neck

Overview and objectives of this dissection

The neck can be thought of as a column or pipe with several smaller pipes inside it. Each pipe is a wall of connective tissue; most structures run superiorly and inferiorly (up and down) inside one particular space between these walls of connective tissue. The outermost column is, of course, the skin. Anteriorly (in the front of the neck), immediately beneath the skin lies the platysma (this muscle will have been exposed by the peeling of the skin in the dissection of the facial regions, because it is thin and inserts into the skin). If you tense the muscles of your neck you can observe your platysma muscles. We will be more concerned with two groups of muscles: the strap muscles of the neck, which lie deep to the platysma muscle, and the muscles forming the floor of the oral cavity, underneath the tongue .

Before beginning the dissection, note the following bony and cartilaginous landmarks, which you should be able to feel on your own neck. It is worth gaining a good understanding of these landmarks before pursuing the dissection because they will be used to locate the muscles in the anterior region of the neck. These locations of these landmarks are illustrated in Figure 4.1. They are also shown in figure 4.3.

The hyoid bone, which lies between the floor of the mouth and the upper end of the neck. Palpate this bone with a thumb and finger on either side of your neck, close to the mandible. You should be able to feel the movements of the cornu (horns) of the hyoid bone by doing the following:

Swallowing.

Saying the vowel sequence [i-a]; noting the higher position of the hyoid bone for the higher vowel.

Saying a single vowel on different pitches. Usually, the higher the pitch, the higher the position of the hyoid bone, though individuals differ in this respect.

The thyroid cartilage, which is the large cartilage of the larynx, forming the major part of the laryngeal prominence (Adam's apple). This will be larger in men than in women. Feel the movements of the thyroid cartilage by repeating the exercises suggested above.

The cricoid cartilage, which is inferior to the thyroid cartilage and sits on top of the first ring of the trachea. Its movements can also be felt by doing the previously suggested exercises.

New Picture
on its way

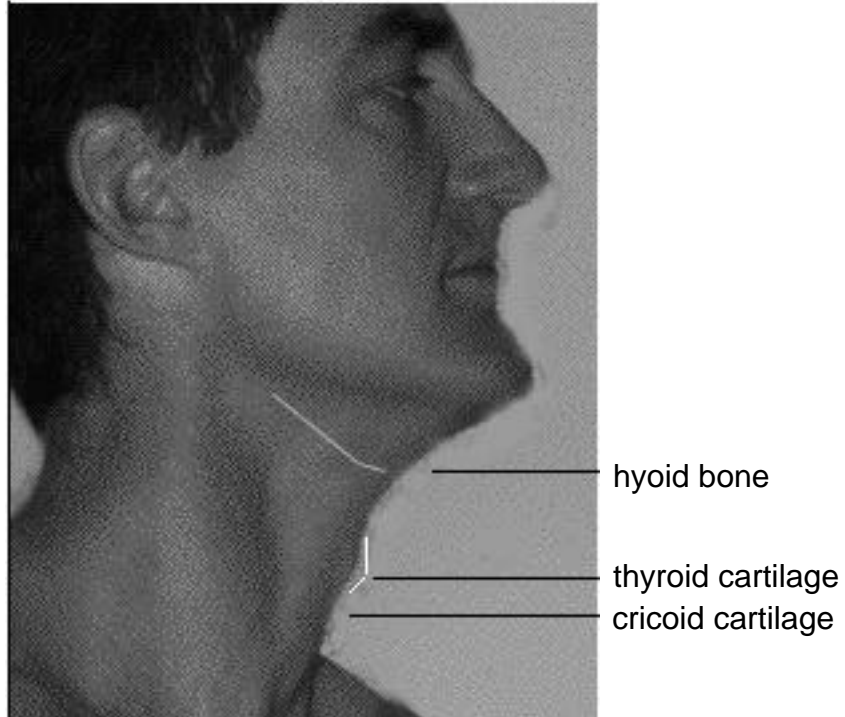


Figure 4.1 A photograph illustrating where the hyoid, thyroid, and cricoid cartilages and the tracheal rings can be felt.

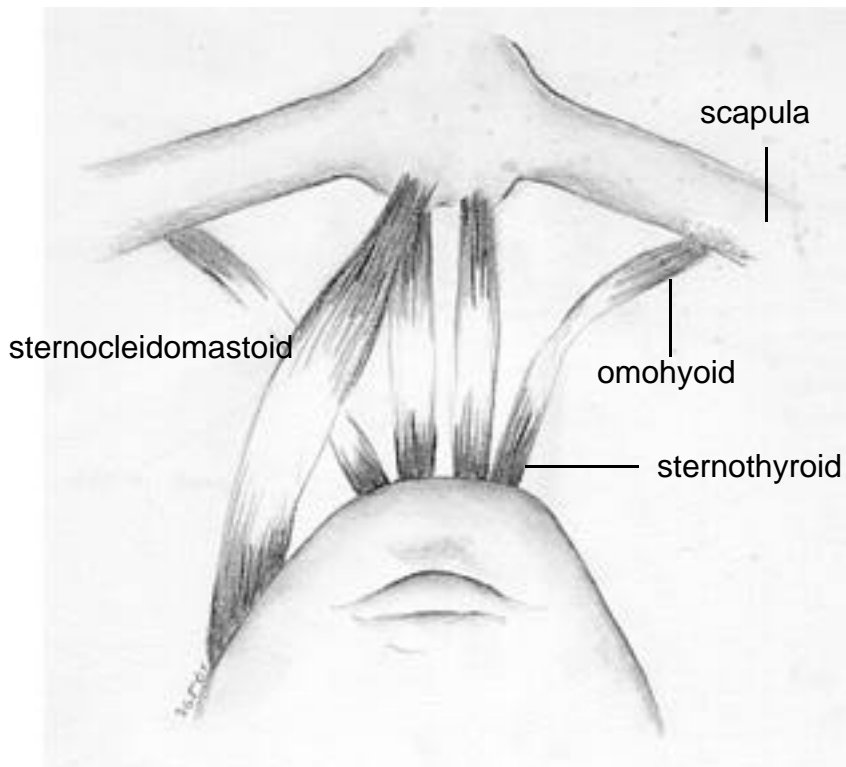


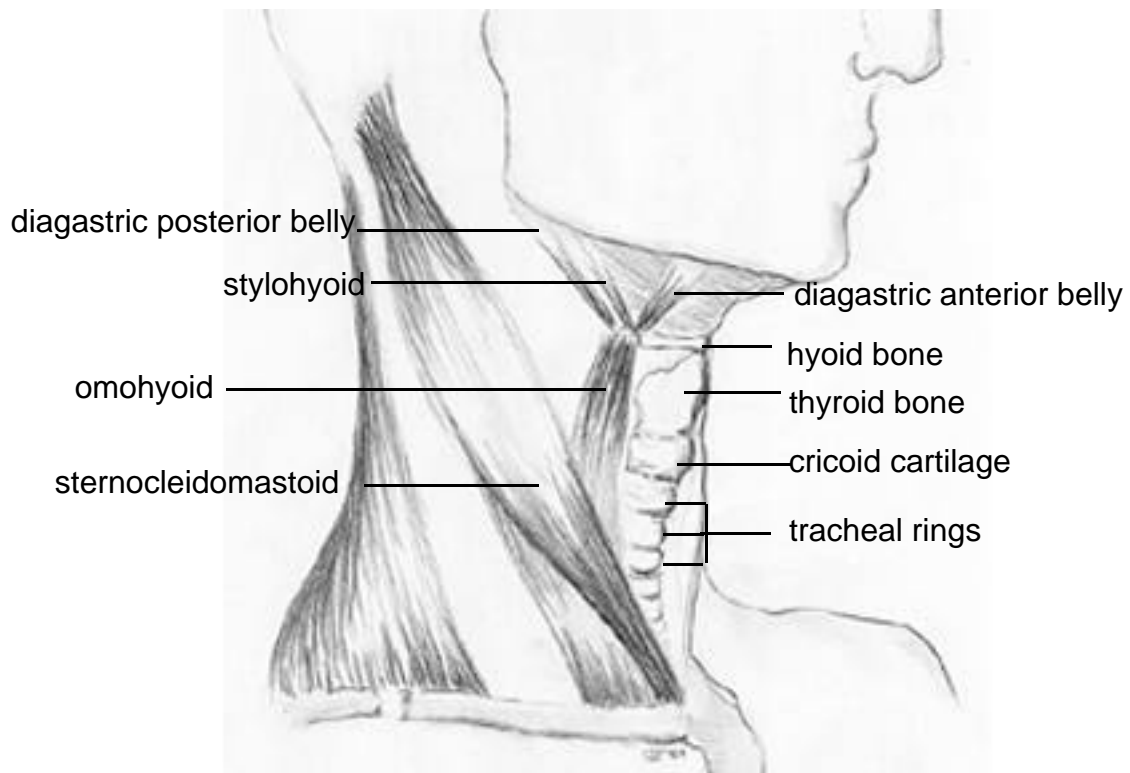
Figure 4.2. The sternocleidomastoid and the outer layer of strap muscles.

The sternocleidomastoid muscle, a major muscle of the neck, runs from the skull just poste-
2

rior to the angle of the mandible to the sternum (i.e. from your skull to your breastbone). From the point of speech production, more important are the four primary strap muscles, so called because they resemble a barber’s strap (used to sharpen blades) or a strap on a horse saddle. They are of concern in speech production in that they control the position of the hyoid bone, and affect the raising and lowering of the larynx. These muscles are located in two layers beneath the platysma muscle and the sternocleidomastoid muscle. The superficial layer consists of two muscles, (1) sternohyoid and (2) omohyoid. These muscles are illustrated in figure 4.2.

The internal layer consists of the two other muscles: (3) thyrohyoid and (4) sternothyroid, which are illustrated in figure 4.3. The superficial strap muscles cover the internal layer of strap muscles.

Figure 4.3. The inner layer of strap muscles and the landmarks of the neck.



After removing all these muscles you will be able to find the recurrent laryngeal nerve, a branch of the vagus nerve. The recurrent laryngeal nerve supplies motor innervation to the intrinsic muscles of the larynx and is thus of prime importance in the production of voiced sounds. If it is injured it is impossible to speak normally. It is called “recurrent” because it starts descending towards the heart, but one branch loops back up to innervate the larynx. The left recurrent laryngeal nerve loops around the aorta, while the right hooks around the right subclavian artery.

The two muscles that form part of the floor of the mouth are the other group of muscles to be investigated. The first, the digastric muscle, consists of two separate bellies (muscle bodies) connected together by a tendon (digastric meaning “two bellies” in Latin). The anterior belly attaches to the mandible anteriorly and runs along the hyoid bone where it passes through a fibrous sling attached to the hyoid. After passing through the sling, the muscle forms the posteri-

or belly, which continues to the medial surface of the mastoid prominence, behind and beneath the ear, Thus it runs downwards from the jaw, through a fibrous sling attached to the hyoid bone, and then back to the skull.

Dissection

The goal of this dissection is to observe the following structures: (1) the strap muscles which control the positioning of the larynx and the nerves responsible for their motor innervation, (2) the larynx and its motor nerves, and (3) the muscles forming the floor of the oral cavity and their motor nerves. It is convenient to dissect these structures from the outside and work inwards, thus starting with the strap muscles and then proceeding to the deeper structures.

1. Reflect the skin from the front of the neck in the following steps:

First continue the midline incision from the chin down to the clavicle.

Next reflect back the skin, from the incision line. The platysma, the thin muscle that lies close to the skin, should be removed with the skin at this time.

2. Locate the sternocleidomastoid muscle, which runs from the skull just posterior to the angle of the mandible to the sternum. Find its attachment on the sternum and cut and reflect this muscle laterally from the sternum. This will expose some of the strap muscles of the neck.
3. Locate the two pairs of superficial strap muscles, the sternohyoid and omohyoid. The sternohyoid muscles originate at the back of the joint between the clavicle and the breastbone (the manubrium of the sternum) and inserts into the inferior border of the hyoid bone. Lateral to the sternohyoid muscles are the omohyoid muscles. These muscles originate at the shoulder blades (scapula) and insert into the inferior border of the hyoid bone. Like the digastric muscles discussed below, the omohyoid muscles also have two bellies.
4. Cut and reflect the sternohyoid muscles and omohyoid muscles at their inferior attachments.
5. Locate the two pairs of internal strap muscles, the sternothyroid and the thyrohyoid. The sternothyroid muscles originate at the manubrium and first rib cartilage and insert into the thyroid cartilage. The thyrohyoid muscles originate at the thyroid cartilage and insert into the greater horn of the hyoid bone.
6. Locate the digastric muscle. This muscle consists of two separate bellies (muscle bodies) connected together by a tendon (digastric meaning “two bellies” in Latin). The digastric muscle basically runs from the jaw to the skull. The anterior belly of the digastric attaches to the mandible anteriorly and runs along the hyoid bone where it passes through a fibrous sling, which is attached to the hyoid. The portion of the digastric which passes through the sling is not muscle but tendon. After passing through the sling, the muscle becomes the posterior belly of the digastric which attaches posteriorly to the medial surface of the mastoid prominence, behind and beneath the ear. Note that there is no direct attachment of the digastric muscle to the hyoid bone.
7. Locate the mylohyoid muscle, which is the floor of the oral cavity. The mylohyoid arises from both sides of the inside of the mandible; each side inserting into a midline raphe (a seam-like ridge or furrow joining two different muscles) and joining with the mylohyoid

muscle from the opposite side. The left and right mylohyoid muscles together form a sling which supports the body of the tongue.

8. Section and reflect the sternothyroid muscle along its inferior attachments to reveal the thyroid gland. The thyroid gland consists of two pyramidal lobes joined together by a narrow strip anterior to tracheal rings 2, 3, and 4.
9. Remove the thyroid gland by disconnecting its vascular supply and disconnecting it completely from the trachea.
10. Explore the C-shaped cartilages of the trachea (first note in chapter 1) inserting your finger behind the trachea. The cartilages are joined together by a fibrous elastic membrane. Posteriorly, the gaps in the C-shaped cartilages are closed by smooth muscle, the trachealis muscle. The trachealis muscle rests against the anterior wall of the esophagus.
11. Locate the recurrent laryngeal nerve between the trachea and esophagus. The recurrent laryngeal nerve is a branch of the vagus nerve and supplies motor innervation to the intrinsic muscles of the larynx. The laryngeal nerve is called “recurrent” because it starts descending towards the heart, but one branch loops back up to innervate the larynx. The left recurrent laryngeal nerve loops around the aorta, while the right hooks around the right subclavian artery.