

7. The Tongue

This portion of the dissection will concentrate on the muscles of the tongue. These muscles are divided into extrinsic (originating outside the tongue) and intrinsic (situated within the tongue) muscles. First, we examine the attachments of the tongue's extrinsic muscles and attempt to understand how they serve to move and shape the tongue during speech. Then, we bisect the tongue and excise one half. This will allow us to examine the tongue's intrinsic muscles and how they serve to move and shape the tongue during speech.

The four major extrinsic muscles of the tongue are shown in figure 7.1:

The mylohyoid muscle, which is responsible for raising the body of the tongue in high vowels and velar consonants.

The hyoglossus, which pulls it downwards (and slightly backwards).

The styloglossus, which pulls the tongue upwards and backwards.

The genioglossus, which forms the bulk of the inferior part of the tongue and pulls the body of the tongue forwards.

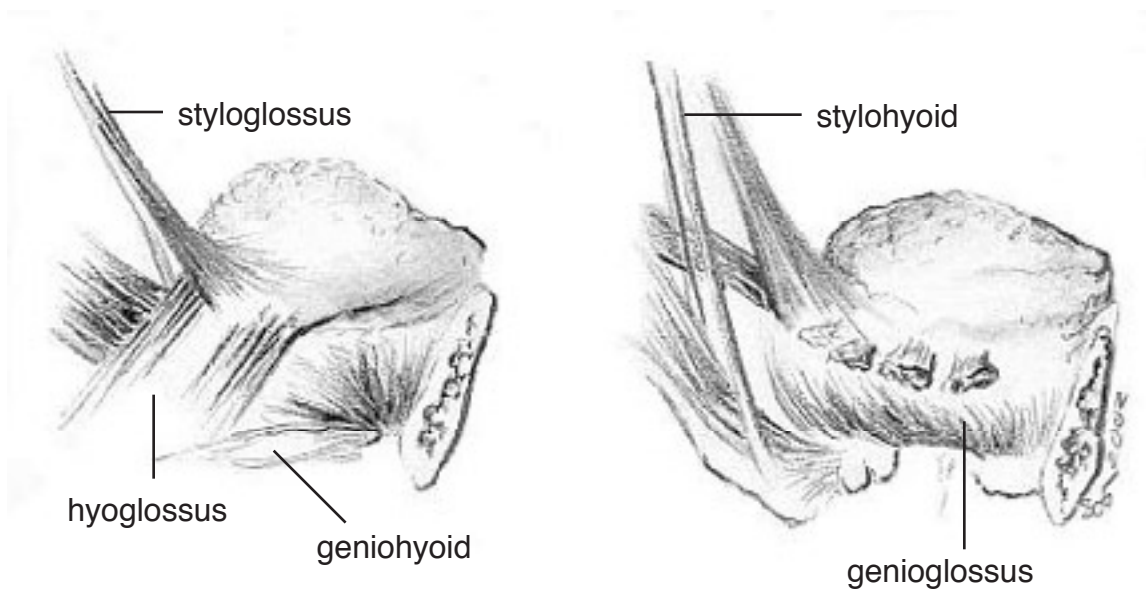


Figure 7.1. The extrinsic muscles of the tongue.

We have already observed the mylohyoid muscle in Section 4. It forms the floor of the mouth and controls the raising of the tongue. It is also an elevator of the hyoid bone, and hence elevates the larynx. The hyoglossus is a broad, flat muscle running from the greater horn of the hyoid to the posteroinferior lateral aspects of the tongue (on the sides of the lower back of the tongue). It is a depressor (lowerer) of the tongue. The styloglossus extends from the styloid process, a projection of the skull at about the level of the ear down into the lateral aspect of the tongue, interdigitating with the inserting fibers of the hyoglossus. The genioglossus is attached to a point on the mandible about halfway between the chin and the lower incisors (front teeth). (Check by feeling with a forefinger down behind the lower front teeth in your own mouth, and

noting where this muscle attaches.) From this point, the muscle fibers fan out posteriorly and superiorly (backwards and upwards) to form the inferior portion of the tongue.

In addition to these four muscles, we will also note two other muscles. The first is the palatoglossus muscle, a small muscle that can assist the action of the styloglossus. The palatoglossus muscle can be found on the posterolateral (back, side) aspect of the tongue below the mucous membrane of the anterior faucal pillar (located on the walls of the mouth on either side of the uvula). From the undersurface of the soft palate, this muscle curves inferiorly (downwards) to insert into the side of the tongue. The second muscle is the palatopharyngeus muscle, which forms the posterior faucal pillars. It does not affect the position of the tongue. The palatoglossus is innervated by the vagus nerve (the Xth), whereas all the other tongue muscles are innervated by the hypoglossal nerve (the XIIth).

The intrinsic muscles of the tongue that we will examine are shown in figure 7.2:

The superior longitudinal muscle, with fibers that run anteroposteriorly (from the front to the back) along the superior surface of the tongue, just below the mucous membrane.

The inferior longitudinal muscle, with fibers that run along the sides of the tongue, from the root to the tip of the tongue. Anteriorly (to the front) these fibers join those of the styloglossus muscle.

The verticalis muscle, with fibers that arise near the midline of the superior surface of the tongue and course inferolaterally (down and to the sides) to insert into the sides of the tongue.

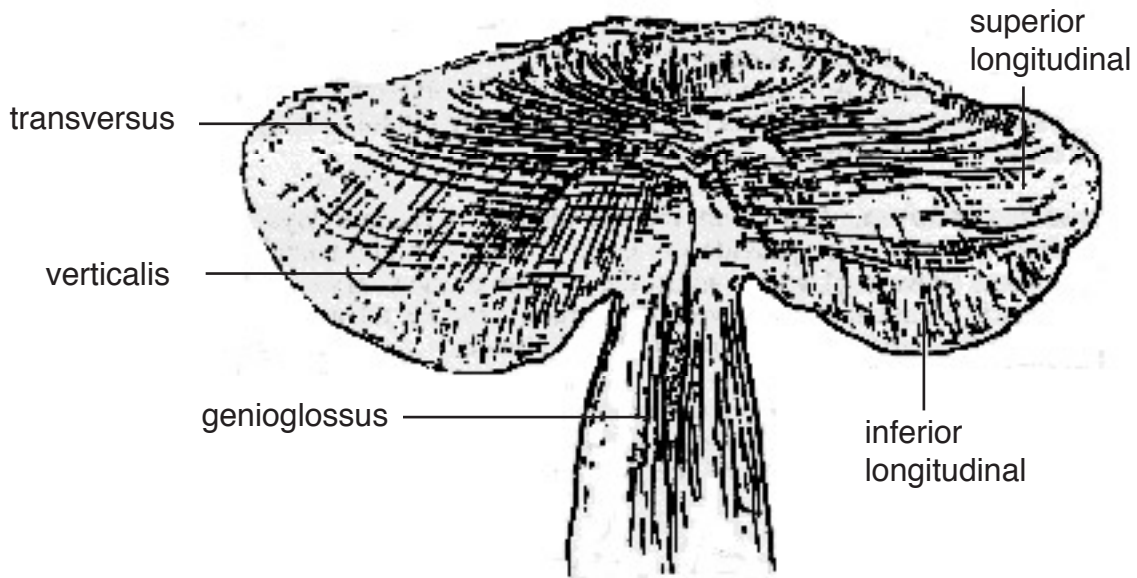


Figure 7.2. A coronal section of the tongue. Note the complexity of the intertwined muscle fibers. (Based on Abd-el-Malek (1939); for another view drawn during a dissection, see figure 7.6.)

The transversalis muscle, with fibers that extend from the mucous membrane on the sides of the tongue to the median septum, which divides the tongue in half sagittally (down the midline).

The actions of some of the muscles of the tongue are summarized in Figure 7.3.

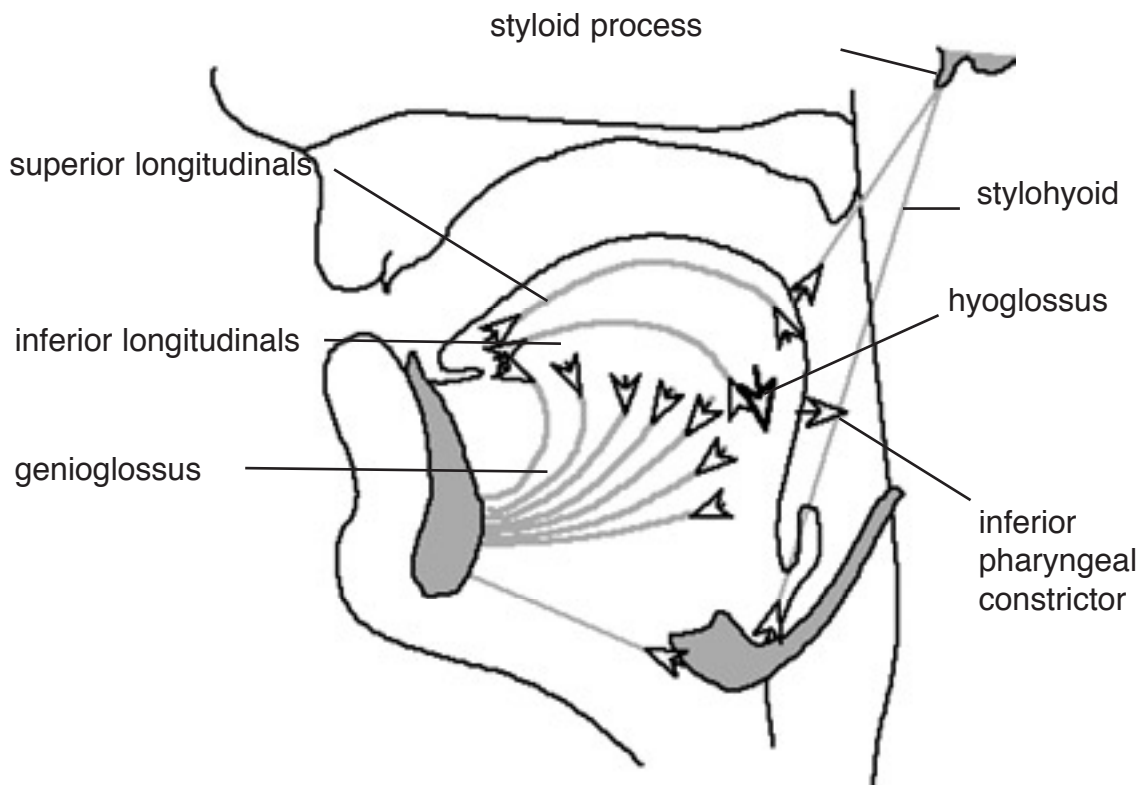


Figure 7.3. Schematic diagram of the actions of some of the muscles of the tongue.

Dissection

This dissection will consist of two parts, first exposing and dissecting the extrinsic muscles of the tongue, and then exploring the intrinsic muscles. Before beginning you should identify structures on the tongue service..

papillae (bumps on the tongue)

foramen caecum (the little pouch on the root of the tongue)

frenulum (the connective tissue between the underside of the body of the tongue and the mylohyoid muscle)

vallae (two shallow oval pits formed by the membrane between the tongue and the epiglottis; food passes through them)

In order to fully examine the extrinsic muscles of the tongue, the dissection must be done from two separate directions. The mylohyoid, hyoglossus and genioglossus muscles will be exposed from below. The styloglossus will be exposed from behind.

Dissecting the tongue from underneath (figure 7.4)

1. Cut the right and left anterior bellies of the digastric as close as possible to the mandible. (This muscle was discussed in chapter 4; see figure 4.3.)
2. Reflect both bellies of the digastric muscle down towards the hyoid bone.
3. Clean away all fat from the mylohyoid muscle and remove the rest of the submandibular gland. Note that the mylohyoid originates from the myloid (interior) ridge of the mandible on each side and meets at its midline raphe. The mylohyoid muscle then inserts at the anterior part of the hyoid bone. Find the posterior border of the mylohyoid muscle and locate the origin of the hyoglossus muscle near this point.
4. Section and reflect the hyoglossus at its superior attachment, revealing the tongue.

New figure to come

Figure 7.4. Dissection of the tongue from below

Exposing the extrinsic muscles of the tongue from behind

1. Turn the head of the cadaver over so you are now approaching it from the posterior aspect of the neck.
2. Locate the part of the stylopharyngeus muscle (figure 6.1) where it passes between the medial and superior pharyngeal constrictors and separate it from the surrounding tissue. Clean up toward the styloid process.
3. Locate the lower end of the stylohyoid muscle (figure 4.3) where it wraps around the tendon of the digastric muscle just above the hyoid bone. Follow the stylohyoid muscle up to the styloid process, just behind the ear.
4. Locate the styloglossus muscle beneath the stylopharyngeus and stylohyoid.

Exposing the side of the tongue

1. Turn to the side of the head where the mandible has already been opened during the dissection of the jaw (figure 7.5).
2. Cut and remove a small piece of the mandible below the coronoid process and above the angle of the mandible. Locate the styloglossus muscle. Locate the inferior alveolar nerve, on the inside of the mandible.
3. Sever the mylohyoid muscle close to the mandible, if you have not done so already, and reflect it medially and inferiorly.
4. Locate the styloglossus and hyoglossus muscles beneath the severed mylohyoid muscle. Some fibers of the styloglossus may form a raphe or interdigitate with the hyoglossus; other fibers may pass superficially over the hyoglossus and enter the tongue.
5. Locate the visible portions of the genioglossus and the geniohyoid.

New figure to come+

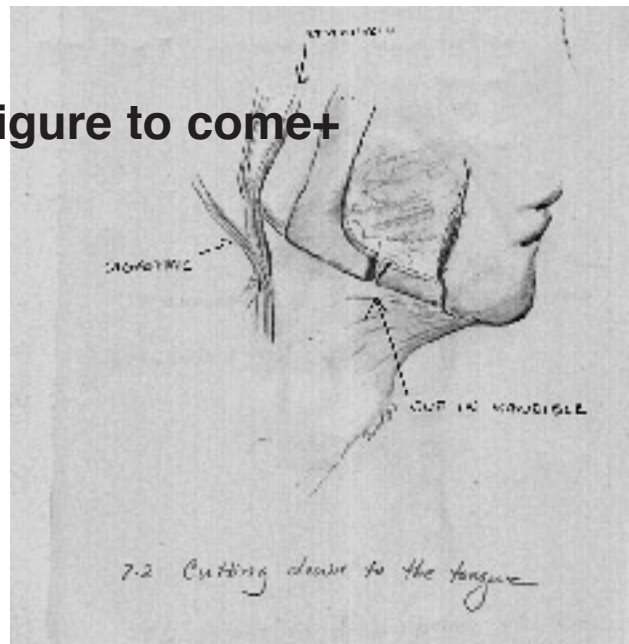


Figure 7.5, Exposing the side of the tongue

6. Detach the mylohyoid muscle from the hyoid bone, completely exposing the geniohyoid muscle.
7. Detach the geniohyoid muscle from the geniohyoid process (the chin), and reflect it inferiorly.
8. Locate the paired genioglossus muscles on the interior of the mandible at the chin. Locate the course of the inferior fibers of the genioglossus. A small group of inferior and lateral fibers of this muscle attach to the hyoid bone. Follow the fibers of the inferior surface of the genioglossus muscle down medially, deep to the hyoid bone, and observe how they insert into the root of the epiglottis.

9. Insert a probe along the inferior aspect of the genioglossus, between the genioglossus and the geniohyoid. Then, posteriorly (i.e. from within the pharynx, from the back) feel the tip of the probe in the neighborhood of the epiglottis. This will clarify the relation of the genioglossus and the epiglottis.
10. Detach the hyoglossus from the hyoid bone, and reflect it superiorly, revealing the parts of the styloglossus muscle which pass deep to the hyoglossus and enter the inferior part of the tongue.
11. Locate the fibers of the genioglossus muscle that pass lateral to the stylopharyngeus muscle and insert into the medial pharyngeal constrictor muscle.

The palatoglossus muscle

Locate the palatoglossus muscle. The palatoglossus muscle forms the anterior portion of the arch from which the uvula hangs, known as the pillar of the fauces. From the undersurface of the soft palate, the palatoglossus curves downward to insert into the side of the tongue. The posterior portion of the pillar of the fauces is formed by the palatopharyngeus muscle.

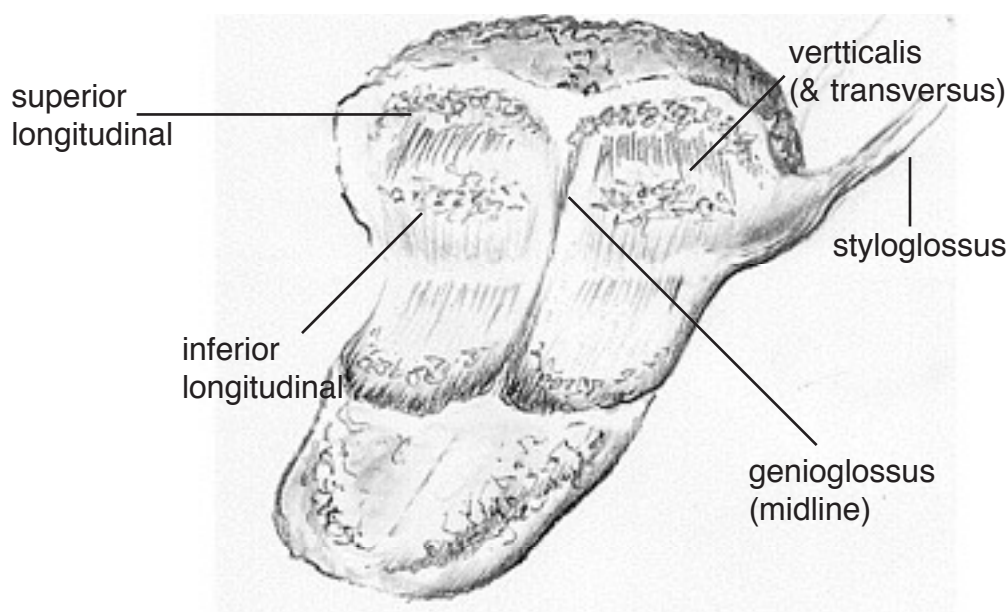


Figure 7.6 A coronal section of the tongue (for a whole tongue, rather than just one half) viewed from behind.

The intrinsic muscles of the tongue

Note: it is very difficult to distinguish all these muscles

1. Bisect the tongue with a sharp scalpel just lateral to the midline, revealing a mid-sagittal section of the tongue.
2. Observe the fanning out of the genioglossus muscle on the sectioned edge.
3. Locate the superior longitudinal muscle in the region of the tongue tip. These muscle fibers

run slightly below the surface of the tongue through its entire length. They fan out from posterior to anterior to attach to the mucous membrane of the tongue. The most inferior fibers attach to the body of the hyoid bone.

4. Remove one of the halves of the tongue from the mouth by cutting as close to its lower attachments as possible.
5. Cut the excised half of the tongue coronally into successive slices.
6. Locate the transversus muscle fibers in the sections. The fibers of the transversus muscles originate near the median fibrous septum of the tongue and run laterally to insert into the muscles of the side of the tongue, i.e. they run transversely.
7. Locate the verticalis muscle fibers in the sections from the forepart of the tongue. These fibers run superoinferiorly, i.e. vertically.
8. Remove the skin from the underside of the half of the tongue remaining in the jaw. This will expose the inferior longitudinal muscle.
9. Observe the styloglossus and hyoglossus merging with the fibers of the intrinsic muscles of the tongue. Follow the course of these muscle fibers to the apex of the tongue.
10. Locate the boundary between the inferior longitudinal muscle and the genioglossus near where the tongue rests within the jaw.
11. Identify and separate out with a probe the different fibers of the intrinsic muscles of the tongue.